# Periodontal regenerative potential using enamel matrix proteins (EMDOGAIN®)

**Lars Heijl**

Med Emdogain® har man för första gången möjlighet att återskapa ett förlorat tandfäste på ett naturligt sätt. Produkten är baserad på användningen av emaljproteiner för att regenerera tandfäste genom att efterlikna den ursprungliga tandbildningsprocessen. Produkten är enkel att använda, de kliniska resultaten indikerar en god förutsägbarhet och användningen dokumenteras fortlöpande. Det förefaller som om Emdogain® även har en positiv inverkan på den postoperativa sårläkningen, något som tilltalar både patienter och tandläkare. Emdogain® och den biologiska filosofi produkten representerar innebär ett nytt sätt att återskapa tandfäste och har öppnat nya perspektiv inom parodontal regeneration, vilket dokumenterats såväl i djurexperimentella studier som i kliniska multicenterstudier.

One way to attempt periodontal regeneration is to mimic the biologic processes involved in nascent tooth development, especially the development of the root and the supporting tissues. The EMDOGAIN® (BIORA AB, Malmö, Sweden) concept is based on the discovery that enamel matrix proteins are not only involved in enamel formation but also play a key role in the formation of acellular cementum [1, 2].

## The biological concept

During the development of the root and the periodontal tissues, an extension of the dental organ, called Hertwig's epithelial root sheath, starts to grow in an apical direction from the cervical area to form the mold for the root. Continuously during root development and always at the mineralizing front of the dentine, the cells of Hertwig's root sheath will enter into a secretory phase. Subsequently, these cells will secrete and deposit enamel matrix proteins onto the surface of the developing root along the mineralizing front of dentine. Following the separation/fenestration of the root sheath, the surrounding mesenchymal cells will migrate through the fenestrations in the root sheath to colonize this surface matrix of enamel proteins, express a cementoblast phenotype, and start forming collagen and acellular cementum. Subsequently, and in sequence, a periodontal ligament and alveolar bone will form.

The first animal experiments to explore if, in fact, enamel matrix proteins could initiate regeneration or reformation of acellular cementum were performed in a reimplantation model in monkeys [2]. The lateral incisors were gently extracted and a standardized experimental root cavity was made under saline irrigation on the

## Author

Lars Heijl, LDS, Odont Dr, Associate Professor, Department of Periodontology, Göteborg University and Medical Director at BIORA AB, Malmö, Sweden.

## Key words

Periodontal regeneration; enamel matrix proteins

Accepted for publication September 1998

mesial surface of the tooth by means of a dental round bur. The cavities in the test teeth were then filled with an enamel matrix preparation before reimplantation while the control teeth were reimplanted without anything being placed in the experimental cavities. In the non-treated control cavities, healing after 8 weeks was characterized by the formation of an intrinsic fibre hard tissue that was poorly attached, thick, often cellular, and had the appearance of immature bone (Figure 1). A characteristic feature of the adjacent connective tissue was that the collagen fibres were running parallell to the surface of the newly formed hard tissue. In contrast, healing in the test cavities prepared with enamel matrix was characterized by the formation of a thin, acellular extrinsic fibre hard tissue with inserting collagen fibres, i.e. a hard tissue with the morphological characteristics of acellular cementum (Figure 2).

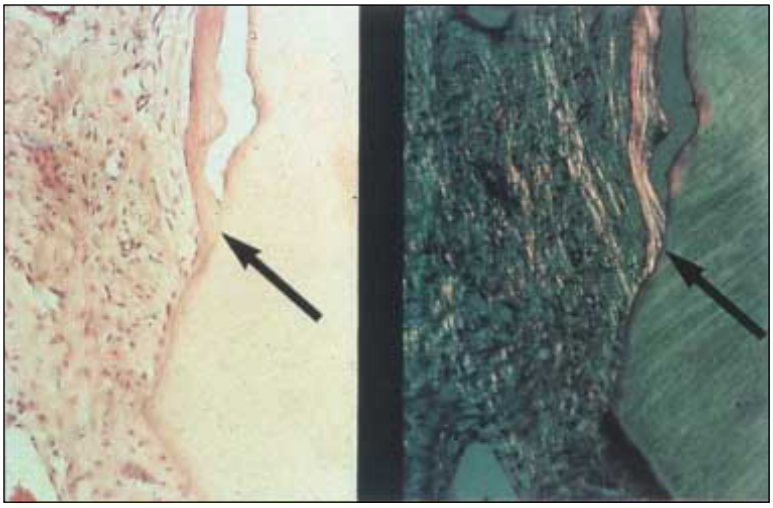

**Figure 1**. Experimental cavity in the root of a lateral incisor of a monkey. After reimplantation and 8 weeks healing, the cavity in a control tooth is covered by an intrinsic fibre hard tissue that is poorly attached, thick, and has the appearance of immature bone (arrow heads). In polarized light the collagen fibres are seen running parallell to the surface of the newly formed hard tissue. Haematoxylin and eosin; normal (left) and polarized (right) light.

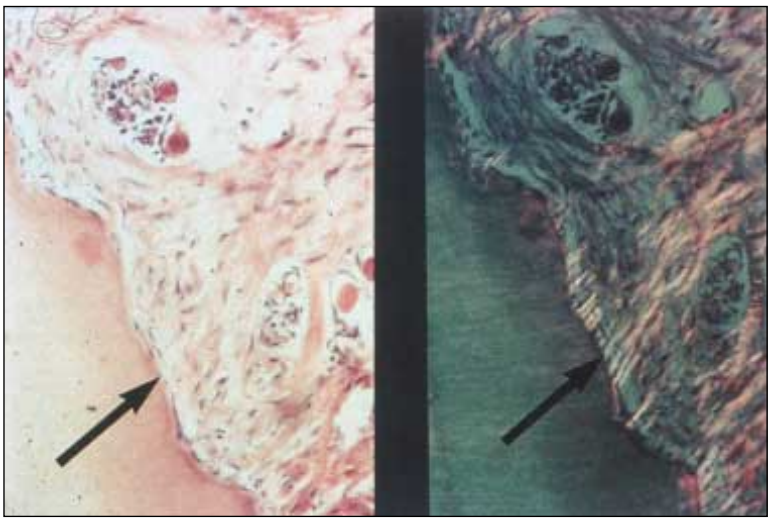

**Figure 2**. Experimental cavity in the root of a lateral incisor of a monkey. After reimplantation and 8 weeks healing, the cavity, where enamel matrix proteins had been placed, is covered by a thin, acellular extrinsic fibre hard tissue with inserting collagen fibres, i.e. a hard tissue with the morphological characteristics of acellular cementum (arrow heads). Haematoxylin and eosin; normal (left) and polarized (right) light.

After the demonstration that an enamel matrix, locally applied on a dentine surface, can induce reformation of acellular cementum, the dehiscence model in monkeys was used to further explore if application of enamel matrix proteins onto denuded root surfaces could promote periodontal regeneration [3]. Another purpose of this extensive series of monkey studies was to find a suitable vehicle to facilitate the application of an enamel matrix preparation onto exposed root surfaces [4]. Contralateral flaps were raised from the maxillary canine to the first maxillary molar. Under irrigation with saline, the buccal alveolar bone as well as the periodontal ligament and cementum of the first and second premolars and the mesial root of the first molar were removed. Care was taken to remove at least the buccal half of the interproximal as well as the interradicular alveolar bone. A bevel was created at the apical end of the experimental defect to serve as a landmark for future histometric measurements. After the exposed root surfaces were conditioned with 37% orthophosphoric acid for not more than 15 seconds to remove the smear layer [5–7], the enamel matrix preparation was applied to cover all of the buccal surfaces and the flaps were repositioned. In control quadrants, after acid conditioning, either no further treatment was given or a vehicle lacking the proteins was applied before the flaps were repositioned. After 8 weeks, the animals were killed and teeth with the buccal dehiscences prepared for light microscopic analysis.

Healing in test sites was characterized by a predictable and marked reformation of or regain in cementum, periodontal ligament and alveolar bone. The regained cementum was thin, acellular, and firmly attached to the underlying dentine surface. In polarized light it could be seen that collagen fibres originated from within the cementum and extended over to the newly formed alveolar bone. In contrast, teeth in the control quadrants (with or without the vehicle) were characterized by rather a pronounced recession of the gingival tissues and no or only minimal regain of periodontal tissues and bone. In those control teeth where recession was less pronounced, there was still an extensive downgrowth of the junc-

tional epithelium, at times even beyond the apical extent of the experimental defect.

*Conclusion: The results from monkey studies using the dehiscence model indicate the potential of an adjunctive use of enamel matrix proteins to induce regeneration of all periodontal tissues, including acellular cementum, periodontal ligament and alveolar bone, in a way that truly mimics the early, natural development of these tissues. The mechanism behind the initiation of this regenerative process seems to be a matrix-cell interaction between the enamel matrix and undifferentiated progenitor cells in the surrounding periodontal tissues. The supplied protein matrix provides an extracellular environment that stimulates mesenchymal cells to regenerate lost tooth attachment by reinitiating the developmental process that previously occurred during odontogenesis. In addition, these monkey studies demonstrate that propylene glycol alginate is a suitable vehicle for local application of enamel matrix proteins.*

## The product

Based on the above results, which support a new concept for periodontal regeneration, the attempts by EMDOGAIN® to mimic the processes that take place during normal tooth development appear to be good. The major component of EMDOGAIN® is freeze-dried enamel proteins, the amelogenin fraction. The other component of EMDOGAIN® is the vehicle, propylene glycol alginate, which facilitates application onto a denuded root surface. The enamel proteins are extracted and purified from tooth buds of porcine origin. In this respect, it is of interest to note that enamel proteins have been around for at least 350 million years; they have been extremely well conserved throughout evolution and, therefore, a patient's immune system does not consider enamel proteins from another species to be "foreign". That there is no potential for immunological reactions has been confirmed in preclinical local irritation and sensitization studies as well as in a number of separate clinical safety studies (see, e.g. Zetterström et al.; [8]).

EMDOGAIN® is indicated for use in con-

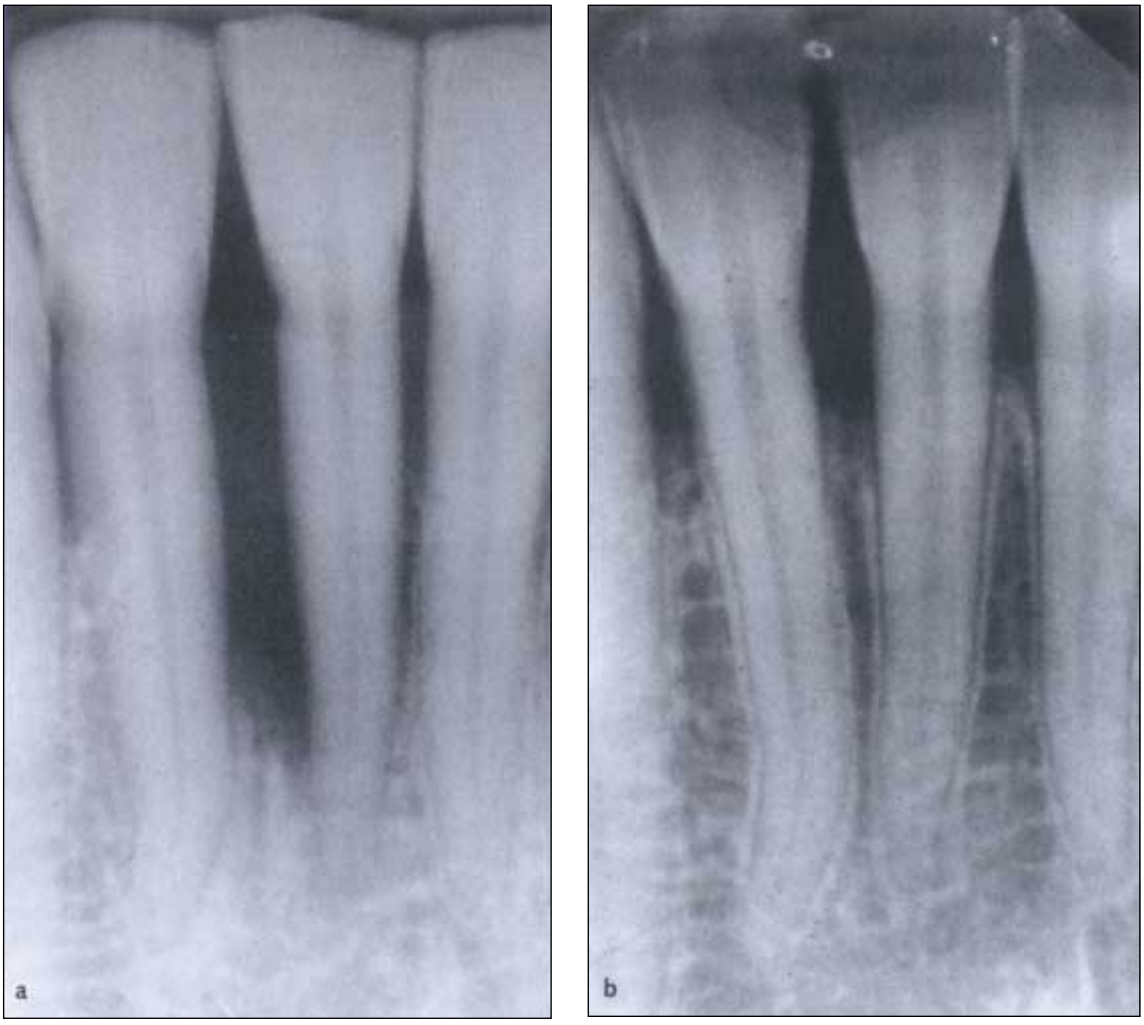


**Figure 3**. **(a)** Radiographs at baseline of an EMDOGAIN® treated site at the distal end of tooth 41 and **(b)** at 7 years post-treatment (female, 38 years, smoker). Courtesy Dr. Gunnar Heden, Karlstad, Sweden.

junction with regenerative periodontal surgery. The two components, the freeze-dried amelogenins and the vehicle, should be mixed immediately prior to surgery to become an easy-to-use syringeable gel. Amelogenins are insoluble at physiological pH but can be dissolved at either low or high pH. The solubility is also temperature-dependent, with solubility increasing at lower temperatures. The propylene glycol alginate vehicle is an acidic vehicle, with a pH below 4.5, which has the right properties for dissolving amelogenin, especially since the vials are refrigerated until mixing (resulting pH in mixture 4.5–5).

## Clinical use of EMDOGAIN®

The principles of the surgical procedure recommended for use in conjunction with EMDOGAIN® are as follows:

Following an intracrevicular incision, a mucoperiosteal access flap is reflected to provide full access to and visibility of the denuded root surface and its associated periodontal defect. It is important to challenge the traditional, more extensive surgical approach and realize that a localized and minimized access flap optimizing wound stability and other parameters affecting periodontal healing should be the approach of choice if periodontal regeneration is the objective. Following removal of granulation tissue, any visible, remaining subgingival plaque and calculus should be removed by scaling. The root surface is then conditioned to remove the smear layer [6, 7]. For proper interaction between the enamel matrix proteins in the EMDOGAIN® formulation and the diseased root surface, it is important that the enamel proteins are allowed to precipitate onto a clean surface, i.e. a root surface devoid of smear and any other organic or inorganic residues. Conditioning with, for example, an EDTA formulation at neutral pH (PrefGel™, BIORA AB, Malmö, Sweden) has been shown to effectively remove the smear layer as well as expose the collagenous matrix of dentine and cementum by selective removal of mineral [9]. It has also been shown that conditioning with PrefGel™ does not interfere with the vitality of the surrounding periodontal tissues. In contrast, the more traditional removal of the smear layer by means of etching with acids (e.g. a saturated citric acid solution or 37% orthophosphoric acid) can interfere with periodontal healing by their necrotizing effect on the surrounding periodontal tissues [10]. Also, it is known that low pH agents denature the collagenous matrix [10]. Thus, to effectively remove the smear layer and at the same time fully utilize the healing potential of the remaining periodontal tissues it is recommended that root surface conditioning be performed either at neutral pH or for a limited time (not more than 15 seconds) with acids.

The surgical area is then carefully rinsed with saline to remove the conditioning agent immediately followed by EMDOGAIN® application. EMDOGAIN® is applied by means of a syringe onto the exposed root surface starting at the most apical bone level and making sure that all




**Figure 4**. **(a)** Radiographs at baseline of an EMDOGAIN® treated site at the mesial surface of tooth 36 and **(b)** at 13 months post-treatment (male, 52 years, non-smoker). Courtesy Dr. Gunnar Heden, Karlstad, Sweden.

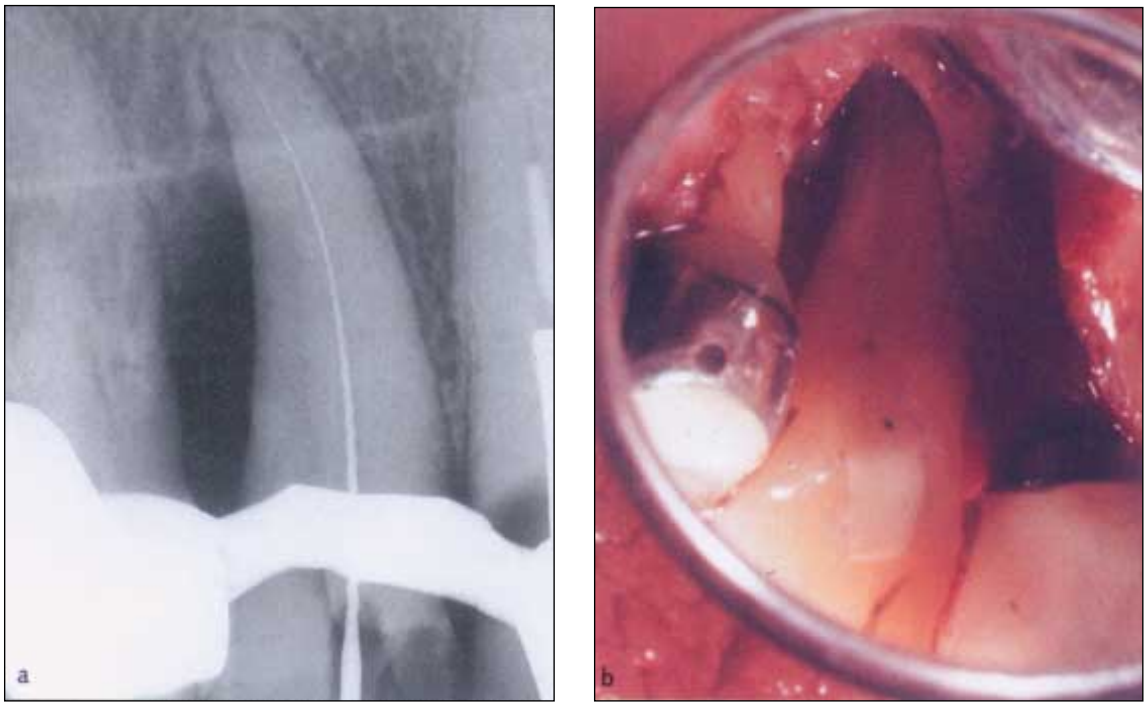



**Figure 5**. **(a)** Baseline radiograph and **(b)** clinical appearance (mirror view) at the time of surgery of an EMDOGAIN® treated defect at the disto-palatal surface of tooth 12. **(c)** Radiographic appearance at 12 months post-treatment (female, 75 years, non-smoker). Courtesy Dr. Gunnar Heden, Karlstad, Sweden.

of the involved root surface is covered. It is imperative to avoid recontamination of the cleaned root surface prior to EMDOGAIN® application. Furthermore, since EMDOGAIN® does not act as a GTR barrier or maintain a space, it is not important to fill the periodontal defect. The only important parameter is to fully cover the exposed root surface with EMDOGAIN®.

Subsequently, the mucoperiosteal flap is replaced and sutured in such a way that primary closure and optimal wound stability is achieved. Overflow of surplus EMDOGAIN® should be expected. Clinical healing of the surgical wound following the use of EMDOGAIN® is usually very rapid and associated with no or only minor post-operative pain, inflammation, and other discomforts.

## Proposed mechanism of healing

It is interesting to describe the suggested sequence of events leading to periodontal healing and starting immediately following suturing of the flaps. Since the solubility of the enamel proteins is both pH and temperature dependent, the facts that (*i*) pH will return to physiological pH and (*ii*) temperature will reach body temperature very soon after the flaps have been replaced and sutured mean that the enamel proteins will start precipitating almost immediately [4]. Thus, aggregates of enamel proteins will adsorb to the root surface and form an insoluble surface matrix which can interact with cells originating in the periodontal ligament and, maybe, endosteal surfaces in marrow spaces, periosteum and vasculature. Detectable amounts of enamel proteins are present at the site of application for up to 2 weeks before being enzymatically degraded. Although this appears to be a sufficiently long period of time to permit colonization of cells having a potential to initiate cementum formation and periodontal regeneration, it is important not

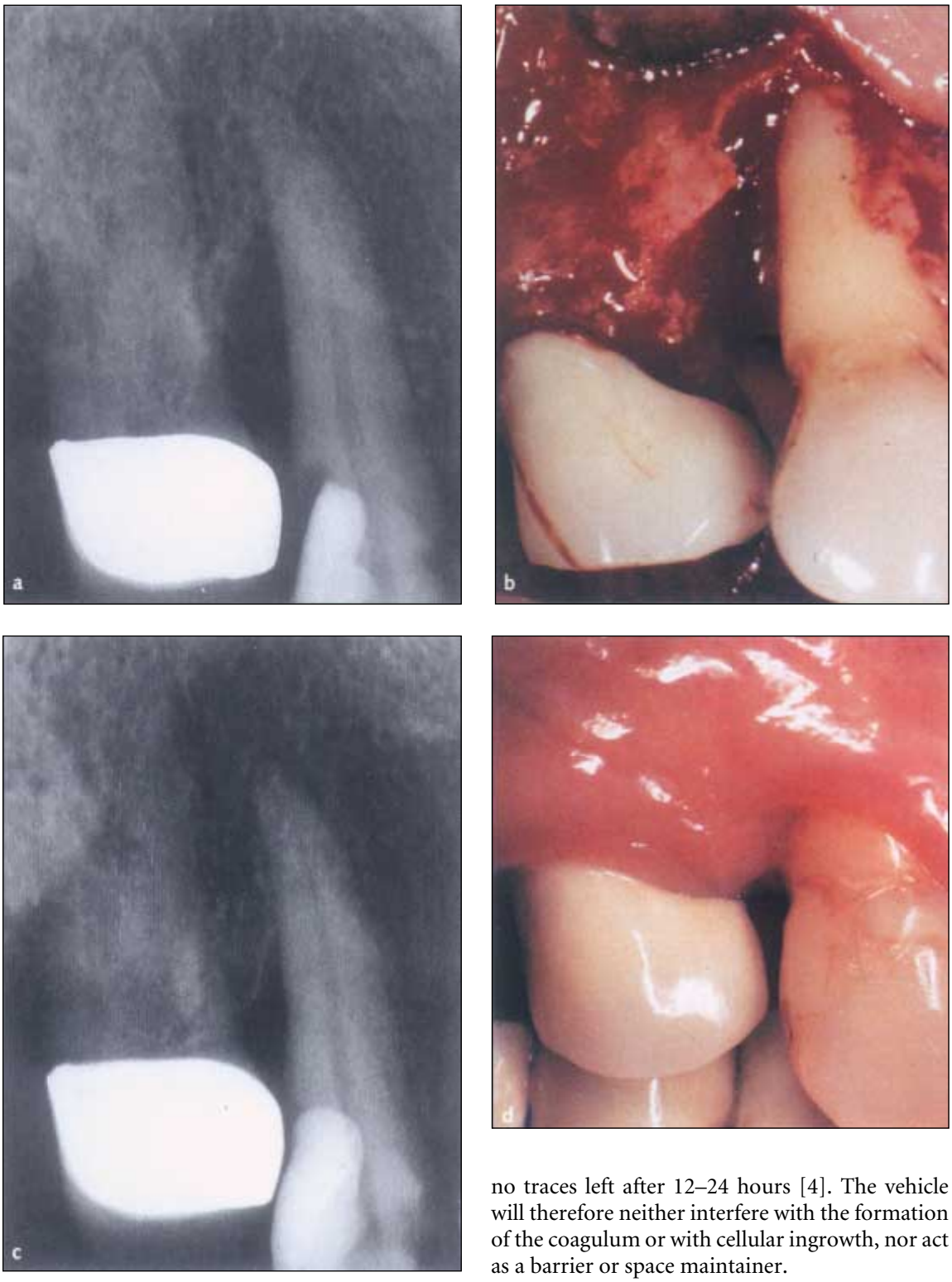

**Figure 6**.
**(a)** Baseline radiograph and **(b)** clinical appearance at the time of surgery of an EMDOGAIN® treated defect at the distal surface of tooth 13.
**(c)** Radiographic and **(d)** clinical appearance at 12 months post-treatment. Note slight recession of soft tissues at 12 months (female, 66 years, non-smoker). Courtesy Dr. Gunnar Heden, Karlstad, Sweden.

to unnecessarily delay wound healing (e.g. do not overuse adrenaline-containing local anaesthetics in the immediate area of the periodontal defect, use a skilful surgical technique, strive for optimal wound stability). Also, the viscosity of the vehicle will change rapidly following flap closure and become very watery. This means that the vehicle will leave the surgical area rapidly and there will be no traces left after 12–24 hours [4]. The vehicle will therefore neither interfere with the formation of the coagulum or with cellular ingrowth, nor act as a barrier or space maintainer.

Within a couple of weeks, a well-organized granulation tissue will have formed in the previous periodontal defect. Based on results from animal experimental studies [2, 3] and *in vitro* studies [11], the healing will be characterized by the enamel matrix surface (*i*) facilitating cementum forming cells to colonize on the root as well as (*ii*) preventing apical downgrowth of epithelial cells. The regained cementum seems to have the













**Figure 7**. **(a)** Radiographic and **(b)** clinical appearance at baseline of an EMDOGAIN®-treated site between teeth 13 and 12. **(c)** Radiographic and clinical appearance at 24 months post-treatment. Note well maintained soft tissue height at 24 months (female, 61 years, smoker). Courtesy Dr. Gunnar Heden, Karlstad, Sweden.

same characteristics as the old cementum and promotes the formation of a new periodontal ligament. Following this regeneration of a functional root cementum and periodontal ligament, the alveolar bone regrows as well [3, 12].

## Human histology

In a human study [13], where histological evidence of periodontal regeneration following the use of EMDOGAIN® was found, a setting which was almost identical to the experiments performed in monkeys and almost identical to the setting intended for clinical use of EMDOGAIN® in humans was utilized. A male patient wanted to have tooth 31 extracted followed by orthodontic treatment and volunteered to have experimental periodontal surgery performed before the tooth was removed. Following reflection of a buccal mucoperiosteal flap, the buccal bone plate was removed almost to the apex of the root. The exposed root surface was then carefully mechanically debrided to assure that no cementum or periodontal ligament remained. Following bone removal, the surgical area was rinsed with sterile saline and the exposed root surface was quickly "etched" with 37% orthophosphoric acid for 15 seconds to remove the smear layer. EMDOGAIN® was then immediately applied to cover the entire exposed root surface. The flaps were replaced and sutured with Goretex™ sutures. After 4 months,

the experimental tooth, together with the surrounding soft and hard periodontal tissues, was removed surgically for histological evaluation.

Morphometric measurements showed that there was a new cementum layer covering 73% of the original defect. Alveolar bone gain was 65% of the presurgical bone height. The histological examination showed the formation of an acellular extrinsic cementum, which was firmly attached to the underlying instrumented dentine surface. The new cementum was thin with inserting collagen fibres, which extended into an associated periodontal membrane. A new alveolar bone attached to the periodontal membrane was also present. This case report demonstrates that EMDOGAIN® has the potential to promote true regeneration of a functional periodontal attachment in an experimental periodontal defect in a human and supports its use in broader human clinical trials.

## Clinical studies

A recent multicentre clinical trial [12] was carried out to compare the effectiveness of EMDOGAIN® treatment as an adjunct to periodontal flap surgery with that of surgery alone in intrabony periodontal defects.

The study was designed as a placebocontrolled, randomized trial at three centres involving 35 patients. The inclusion criteria required two interproximal, comparable sites in the same jaw, i.e. contralateral sites either in the maxilla or in the mandible. Probing pocket depths had to be 6 mm or more and the associated intrabony defect 4 mm or more deep and 2 mm or more wide as judged on radiographs. The clinical endpoints used were radiographic bone level and clinical attachment level. Radiographic bone levels were determined by analysing superimposable and subtractable radiographs. Clinical attachment levels were measured by trained and calibrated examiners.

Further design criteria of importance were that

- only predominant 1- or 2-wall defects were included. Strict or predominant 3-wall defects were *not* included since in these defects surgery alone sometimes has an exceptionally good effect on osseous regrowth [14];
- test and control treatments were assigned at random and surgeries of test and control sites were performed at the same surgical session;
- all measurements, except measurements made during surgery to describe and characterize the intrabony defects, were made by the same, blinded investigator;
- the aim of the post-surgical programme was to maintain optimal wound stability and infection control. The patients were not allowed to perform any mechanical tooth cleaning during the first 6 weeks post-surgery. However, professional supragingival tooth cleaning was performed as needed. The patients received systemic antibiotic therapy for the first 3 weeks post-surgery and rinsed with a 0.2% chlorhexidine solution for 6 weeks post-surgery.

A subset of 33 *per protocol* patients providing 34 pairs of experimental sites were included in the evaluation. Of these patients; 16 were smokers and 17 non-smokers. All surgical sites were examined at 8, 16, and 36 months post-treatment for all clinical parameters measured at baseline.

There were no efforts made to exclude any patients with smoking habits, various systemic disorders, etc. Furthermore, patients included in the trial had been subjected to systematic periodontal treatment including repeated mechanical debridement and therapy supplemented with antimicrobial as well as surgical procedures in the experimental areas. These therapeutic regimens had been performed over long periods of time, which was often several years. The overall assessment of these patients was that they suffered from periodontal disease and associated anatomical defects that were not responsive to conventional periodontal therapy.

At all time points it could be demonstrated that EMDOGAIN®-treated sites were always statistically significantly better than the control sites. At the 3 year follow-up the mean radiographic bone gain in the EMDOGAIN®-treated sites had increased from 2.2 mm at the 16-month examination to 2.6 mm. This equals a 66% defect fill or a 36% regain of initial bone loss. The bone level at the control sites was more or less unchanged after 3 years. This is a dramatic and clinically relevant difference, especially since almost half of the patients were smokers and thus at risk for a negative or less successful treatment outcome.

The results reported in the multicentre trial were subsequently corroborated in a series of 72 consecutively EMDOGAIN®-treated 1- and 2-wall intrabony periodontal defects [15]. Treatment efficacy was evaluated at 12 months post-treatment by assessing probing depth reduction, probing attachment level gain, and radiographic bone gain, from standardized radiographs. At 12 months, the radiographic bone gain averaged 3.1 mm and defect fill averaged 70%. The results of this case report study of EMDOGAIN® treatment of 1- and 2-wall intrabony defects in routine periodontal practice are strikingly similar to those seen in controlled clinical trials with EMDOGAIN® (Figures 3–7).

## How to achieve the best results

Although a high predictability for a favourable outcome following an adjunctive use of EMDOGAIN® has been demonstrated in intrabony defects, it is still important to discuss how to achieve the best results. A basis for this discussion is the understanding that treatment of periodontal patients involves a series of distinctly different steps. A diagnosis of the periodontal pathology is required for an appropriate treatment plan to be established. Infection control (or "cause-related" therapy) is an essential component of the initial treatment. Only when the level of success of the cause-related therapy has been properly evaluated can the content of the corrective therapy, e.g. periodontal surgery to eliminate anatomical defects caused by the disease, be determined. If a decision is made to eliminate remaining defects, the choice has to be made between either a resective surgical technique or a regenerative technique. It is often acceptable to perform resective techniques that eliminate the pockets by means of apically repositioned flaps including bone recontouring. In most cases, however, an obvious choice is a regenerative technique. There are then a number of general factors that need to be controlled if a predictable and favourable outcome is to be expected, whether EMDOGAIN® is used or whether some other regenerative treatment modality is used.

The first factor affecting the outcome of regenerative procedures that needs to be discussed is the use of *local anaesthetics*. It is preferable that the anaesthesia be performed by means of either infiltration anaesthesia or block anaesthesia. The use of injections into the papillae or into the immediate area of the periodontal defects is, in spite of the requirement for haemostasis, not recommended because of the potential risk for a delayed wound healing when local anaesthetics with adrenaline are used. Regarding surgical technique, it is important to understand that technical skill and speed are of importance because both will lessen the trauma to the periodontal tissues, thereby creating more optimal conditions for good wound healing.

Another critical factor is *wound stability*. The importance of a stable wound and a stable initial attachment between the fibrin clot and the root, a so-called stable fibrin-linkage, has been supported by many investigators. The often cherished hypothesis, that there is always a race between the gingival epithelial cells and the gingival periodontal connective tissue cells to cover the wound/root surface, probably has no relevance. Rather, apical migration of epithelium usually occurs as a consequence of a break between the root surface and the healing granulation tissue. Treatment and post-surgical care must therefore include methods to stabilize the periodontal wound during healing and create optimal conditions for wound healing, i.e. the cellular events that will result in the reformation of the periodontium must be allowed to proceed undisturbed. One way of creating a good wound stability in a regenerative surgical procedure is by using a flap design that permits primary and stable closure. Such flaps should be characterized as access flaps, i.e. a minimized flap only involving the periodontal defect(s) to be treated. A good suturing technique using a non-irritating suture, for example a Goretex® or a Vicryl® suture, is essential.

Careful *postoperative instructions* are equally important to maintain wound stability. This includes asking the patient not to chew in the operated area or brush in this area for the first 4-6 weeks. It also means that the treating dentist must take full responsibility for supragingival plaque control during the initial post-surgical healing phase by seeing the patient on a weekly or bi-weekly basis for professional tooth cleaning. Furthermore, in cases of hypermobility (mobility degrees 2 and 3) where occlusal adjustment has been ineffective or is not feasible and unacceptable mobility levels persist prior to EMDOGAIN® treatment, splinting should be considered. Other important factors of a more general nature that need to be considered are long-term plaque control and the systemic status of the patient at the time of surgery and during healing.

*Conclusion: It is important to emphasize that there are a number of general factors affecting the outcome of a regenerative surgical procedure which makes it impossible to obtain a truly predictable regeneration regardless of which procedure or agent, or combination of both, is used, unless these factors are controlled or can be controlled. Therefore, only when these factors are well controlled in EMDOGAIN®-supported regenerative periodontal surgery, can the predictable results reported here be obtained.*

## Summary

When comparing EMDOGAIN® with other regenerative technologies in periodontal therapy it is evident that the regenerative potential in intrabony defects following the use of EMDOGAIN® is at least equal based on clinical parameters, i.e. probing and radiographs. In addition, the postoperative healing following the

use of EMDOGAIN® is impressive. Anecdotal reports from periodontists as well as patients describe uneventful healing with almost no postsurgical discomforts (such as swelling and pain) when EMDOGAIN® is used. Furthermore, the product is easier to use than most other products available for periodontal regeneration. Another advantage following EMDOGAIN® use may be a potential for healing with improved quality and function.

EMDOGAIN®, the first product in a wave of biological solutions in regenerative periodontics, appears to have a potential to raise the limits of what is possible to achieve in regenerative periodontics and thereby improve the standard of care.

## References


1. Hammarström L. The role of enamel matrix proteins in the development of cementum and periodontal tissues. In: Dental enamel (Ciba Foundation Symposium), Chadwick DJ, Cardew G, editors. New York: John Wiley & Sons, 1996; 246–60.
2. Hammarström L. Enamel matrix, cementum development and regeneration. J Clin Periodontol 1997; 24: 658–68.
3. Hammarström L, Heijl L, Gestrelius S. Periodontal regeneration in a buccal dehiscence model in monkeys after application of enamel matrix proteins. J Clin Periodontol 1997; 24: 669–77.
4. Gestrelius S, Andersson C, Johansson A-C, Persson E, Brodin A, Rydhag L, Hammarström L. Formulation of enamel matrix derivative for surface coating. Kinetics and cell colonization. J Clin Periodontol 1997; 24: 678–84.
5. Polson A, Proye M. Effect of root surface alterations on periodontal healing. II. Citric acid treatment of the denuded root. J Clin Periodontol 1982; 9: 441–54.
6. Polson A, Fredrick G, Ladenheim S, Hanes P. The production of a root surface smear-layer by instrumentation and its removal by citric acid. J Periodontol 1984; 55: 443–6.
7. Blomlöf J, Lindskog S. Root surface texture and early cell colonization after different etching modalities. Eur J Dent Sci 1995; 103: 17–24.
8. Zetterström O, Andersson C, Eriksson L, Fredriksson A, Friskopp J, Heden G, Jansson B, Lundgren T, Nilveus R, Olsson A, Renvert S, Salonen L, Sjöström L, Winell A, Östgren A, Gestrelius S. Clinical safety of enamel matrix derivative (EMDOGAIN®) in the treatment of periodontal defects. J Clin Periodontol 1997; 24: 697–704.
9. Blomlöf J, Blomlöf L, Lindskog S. Smear removal and collagen exposure after non-surgical root planing followed by etching with an EDTA gel preparation. J Periodontol 1996; 67: 841–5.
10. Blomlöf J. Root surface conditioning in periodontal treatment. Thesis. Stockholm: Karolinska Institutet, 1997.
11. Gestrelius S, Andersson C, Lidström D, Hammarström L, Somerman M. In vitro studies on periodontal ligament cells and enamel matrix derivative. J Clin Periodontol 1997; 24: 685–92.
12. Heijl L, Heden G, Svärdström G, Östgren A. Enamel matrix derivative (EMDOGAIN®) in the treatment of intrabony periodontal defects. J Clin Periodontol 1997; 24: 705–14.
13. Heijl L. Periodontal regeneration with enamel matrix in one human experimental defect. A case report. J Clin Periodontol 1997; 24: 693–6.
14. Polson A, Heijl L. Osseous repair in infrabony periodontal defects. J Clin Periodontol 1978; 5: 13–23.
15. Heden G. A case report study of 72 consecutive EMDOGAIN® -treated intrabony periodontal defects: Clinical and radiographic findings after 1 year. Int J Periodont Restor Dent 1998: submitted for publication.


*Lecture at the Scandinavian Society of Periodontology Annual Meeting at Kolmården, Sweden, 8–10 May 1998.*

## Address

Lars Heijl, BIORA AB, Ideon/Malmö, SE-205 12 Malmö, Sweden.